

# A Prospective Clinical Evaluation of Biodegradable Neurolac Nerve Guides for Sensory Nerve Repair in the Hand

Mariëtta J. O. E. Bertleff, MD, Marcel F. Meek,  
Jean-Phillipe A. Nicolai, *Groningen, the Netherlands*

**Purpose:** Our purpose was to study the recovery of sensory nerve function after treatment of traumatic peripheral nerve lesions with a biodegradable poly(DL-lactide-ε-caprolactone) Neurolac nerve guide (Polyganics B.V., Groningen, the Netherlands) versus the current standard reconstruction techniques.

**Methods:** Thirty patients with 34 nerve lesions were included in this randomized, multicenter trial.

**Results:** Both groups were comparable considering their demographics. After a small learning curve the nerve guide could be implanted easily. There were more complications in the experimental group but none of them was directly device related. Recovery of sensibility in the nerve guide group was at least as good as in the control group.

**Conclusions:** These results indicate that the Neurolac nerve guide is suitable for the repair of transected peripheral nerves in the hand. (*J Hand Surg* 2005;30A:513–518. Copyright © 2005 by the American Society for Surgery of the Hand.)

**Key words:** Hand surgery, nerve guide, Neurolac, sensory nerve injury.

The most serious form of nerve damage is complete transection and subsequent loss of nerve function. Such a nerve defect has to be restored surgically because spontaneous recovery of the nerve function is not likely to occur. The present standard surgical treatments are (1) direct end-to-end suturing or (2)

harvesting a donor nerve elsewhere from the body and restoring nerve continuity with the graft in case the defect is too large for end-to-end suturing. Both techniques have considerable drawbacks. In the case of direct end-to-end suturing tension may be introduced, which negatively affects the quality of nerve regeneration.<sup>1,2</sup> If an autologous nerve graft is used then a nerve transplant has to be harvested; this results in donor site morbidity such as numbness, painful neuroma, and scar formation.<sup>1,3,4</sup> The use of an artificial nerve guide that can be implanted easily precludes the necessity of such a graft. It is assumed that the nerve conduit will guide the outgrowing nerve fibers from the proximal to the distal stump and that it has a protective function by preventing neuroma formation and the ingrowth of fibrous tissue.<sup>1,3</sup> Also, a nerve guide facilitates growth factors necessary for optimal nerve regeneration to remain locally present and leads to the formation of a microenvi-

From the Department of Plastic Surgery, University Hospital Groningen, Groningen, the Netherlands.

Received for publication February 18, 2004; accepted in revised form December 17, 2004.

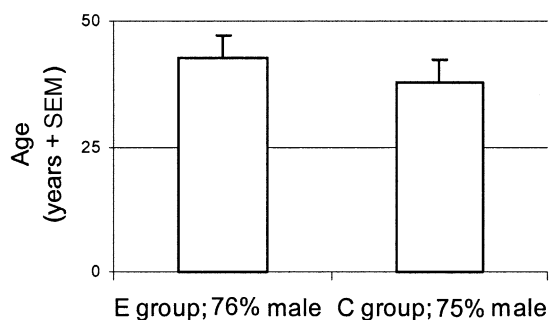
No benefits in any form have been received or will be received from a commercial party related directly or indirectly to the subject of this article.

Supported by Polyganics B.V., Groningen, the Netherlands.

Corresponding author: Mariëtta J. O. E. Bertleff, MD, Department of Plastic Surgery, De Griffioen 11, 7609 SK Almelo, the Netherlands; e-mail: doc.bert@wanadoo.nl.

Copyright © 2005 by the American Society for Surgery of the Hand  
0363-5023/05/30A03-0015\$30.00/0

doi:10.1016/j.jhsa.2004.12.009



**Figure 1.** Patient age, gender, and randomization. E, experimental group receiving nerve guide; C, control group receiving standard treatment.

ronment optimal for nerve regeneration.<sup>2,5-7</sup> After the nerve guide has accomplished its function it degrades and is resorbed. The Neurolac nerve guide (Polyganics B.V., Groningen, the Netherlands) is composed of poly(DL-lactide- $\epsilon$ -caprolactone) and will start to degrade after several weeks. After 1 year it is degraded completely.<sup>8</sup> After many years of experimental research with the Neurolac tube a clinical trial was started.<sup>8-10</sup> The purpose of this study was to evaluate the experience with the Neurolac nerve guide to treat sensory nerve defects in the human hand, distally from the wrist, in terms of adverse events and sensory nerve recovery.

## Patients and Methods

### Study Design

This blind, randomized, multicenter clinical investigation was designed to evaluate the performance and safety of a Neurolac nerve guide for the treatment of peripheral nerve defects up to 20 mm in the hand. In a control group the patients were treated with the current standard repair. All procedures were coordinated and performed under supervision of one hand surgeon in each of the 5 participating hospitals.

### Ethical Considerations

The study was performed according to the Declaration of Helsinki and in agreement with the guidelines for conducting a clinical investigation as outlined in the European Harmonized Standard, EN540. Before each patient participated in the study written informed consent was obtained. The written approval of independent local medical ethics committees was obtained.

### Patient Selection

Between August 2002 and March 2003, 30 patients were enrolled in the trial. All patients between the

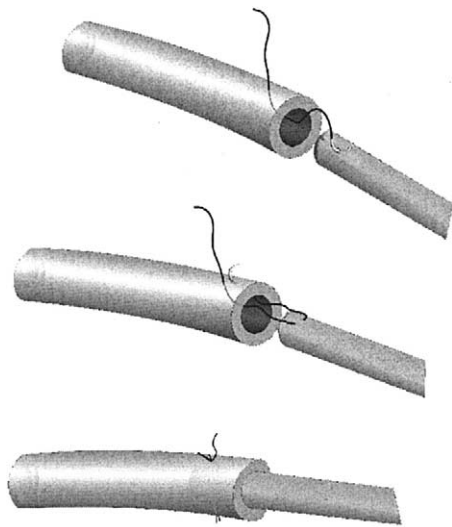
ages of 18 and 75 years with a nerve injury distal to the wrist were included. Exclusion criteria were neuropathy (eg, resulting from diabetes, alcoholism), gout, collagen vascular disease, or the use of immunosuppressive drugs. Patients who met the inclusion criteria were randomized into 1 of the 2 groups. Randomization was performed in the operating room after exploration of the wound. The nerve defect length was measured to determine into which stratum (length  $\leq 4$  mm, length  $> 4$  to  $\leq 8$  mm, or length  $> 8$  to  $\leq 20$  mm) the nerve lesion was allocated. Each group had its own randomization according to the defect called 04, 08, or 20. If more sensory nerves in the hand were transected then 1 primary nerve defect was selected. All other nerve defects that met the inclusion criteria were treated by the same method. In this period 17 patients received 21 Neurolac nerve guides and 13 patients were in the control group in which end-to-end suturing was performed. The age and gender of both groups were well matched (Fig. 1). The overall health status of the patients was good: according to the American Society of Anaesthesiology (ASA) classification 28 patients (93%) were ASA I and 2 patients (7%) were ASA II, equally divided between both groups (Table 1). Twenty-six patients had an injury of a proper ulnar or radial digital nerve; the other 4 patients had an injury of 1 of the common digital nerves in the palm of the hand. Four patients had more than 1 transected nerve, all of whom were in the Neurolac tube group. There were no patients with more than 2 transected nerves. No patients needed repair with an autologous nerve transplant.

### Surgical Technique

According to the hospital protocol a single dose of antibiotics was given before surgery. The injured nerve was dissected under tourniquet control. The gap length (distance between the proximal and distal stumps) was measured with the fingers fully extended; this was performed before and after dissection of the nerve ends. After measuring the gap

**Table 1. Demographics**

Characteristic	Experimental	Control
Male (%)	76	75
Mean age (y)	43	38
Alcohol (U/d)	1	1
Diabetic patient (n)	1	1
ASA 1 (%)	94	92
ASA 2 (%)	6	8



**Figure 2.** Suture technique. (Top) The needle goes from outside the tube into the lumen, (middle) then an epineural stitch is performed. After this, (bottom) it goes from inside the tube to outside, pulling the nerve end into the tube and making a knot.

length one of the nurses in the operating room opened a blinded envelope to randomize the patient into the Neurolac nerve guide group or the control group. Primary suturing was performed with an 8-0 or 9-0 nonabsorbable (Ethilon) suture. It was up to the surgeon to decide to use a nerve graft in case the gap length was too large. If the patient was selected for the Neurolac nerve guide group then the diameter of the nerve was measured and the appropriate tube was selected and cut to the right size. Both nerve ends were pulled into the tube for 4 to 5 mm and each stump was fixed with 1 or 2 epineural 8-0 nonabsorbable sutures (Fig. 2). Because the nerve guides are transparent it was possible to ask the surgeon to measure the gap between both stumps after the suturing procedure; this was zero in the control group. Finally the wound was closed in the usual manner and the hand and/or fingers were splinted with plaster during the first 2 postoperative weeks to immobilize the joint to prevent kinking, compression, and/or extrusion of the nerve guide. In case of a combination of nerve and tendon injury then a dynamic plaster splint was applied, allowing restricted mobilization of the joint for the first 2 weeks to a maximum of 60° of flexion if the tube was positioned over a joint.

### Evaluation of Recovery and Sensibility

In every patient the distance was measured from the level of the nerve injury to the fingertip.

The evaluation of sensory recovery took place at 3, 6, 9, and 12 months after the surgical procedure. Between the participating hospitals it was agreed to measure sensibility on a fixed point, which was the crossing point of a line drawn from the base of the nailbed and a line drawn at the midcentral line. Sensibility was tested by using a noninvasive computer-assisted force transducer that measures static and moving 1- and 2-point discrimination (Pressure-Specified Sensory Device; Sensory Management Services, Lutherville, MD).<sup>11</sup> Patients were checked routinely for any adverse events such as foreign-body responses, inflammation, swelling, infection, bleeding, delayed wound healing, painful scar formation at the nerve reconstruction site, extrusion of the nerve guide, pain and local irritation around the nerve reconstruction site, allergic reactions, and/or remaining hypersensitivity in the reinnervated area.

### Statistical Analysis

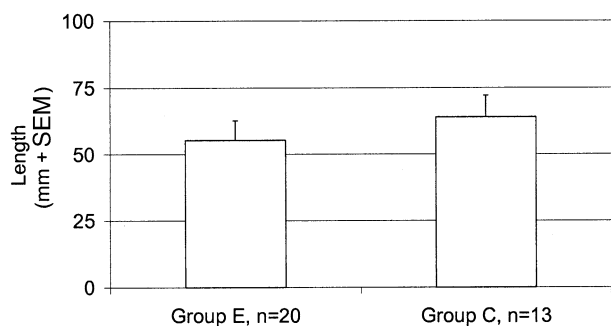
Data were analyzed statistically by an independent data management office (Trial Coordination Centre, Groningen, the Netherlands). The Wilcoxon test, *t* test, chi-square test, and Fisher's exact tests were used.

### Results

The operating time in the experimental group was comparable to the control group (79 vs 82 minutes) (Table 2). If we look at just the time needed for the nerve repair procedure then the repair took longer in the experimental group. The time needed for primary end-to-end repair was 13 minutes (*n* = 13) and the time needed to place the nerve guide was 27 minutes (*n* = 21). Both groups also were comparable when additional injuries were considered (Table 2). There were 19 patients with associated tendon injury, 17 patients also had a laceration of the digital artery, and 5 patients were treated for fractures of the hand. There were 4 patients who had nerve injury to 2 fingers, all of whom were in the experimental group. In the experimental group there were a few more patients with a gap of 8 mm or more (Fig. 4). After

**Table 2. Associated Injuries**

Type of Injury	No. of Patients	
	Experimental	Control
Bony injury	2	3
Artery	8	9
Tendon injury	10	9

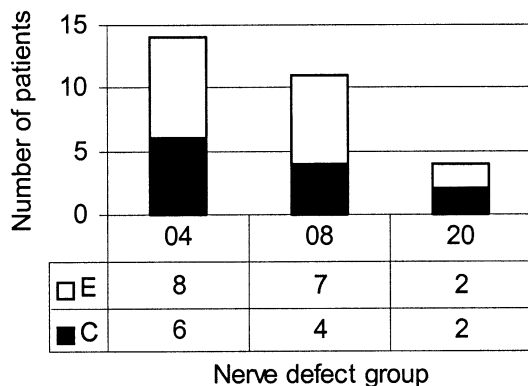


**Figure 3.** Distance between level of nerve lesion and fingertip.

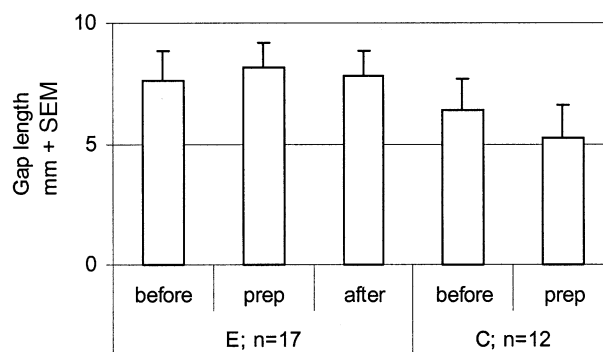
the nerve endings were sutured into the nerve guide the gap length remained unchanged, which meant there was still an average gap of about 6 to 8 mm between the 2 nerve stumps (Fig. 5). There was 1 patient in the control group and there were 3 patients in the experimental group with wound healing problems. In only 2 patients were wound problems directly at the site of the nerve repair but a direct relationship was not certain. Debridement of the wound and removal of the nerve guide were necessary in only 1 of these patients. Two patients in the experimental group needed a second surgery because of rupture of the repaired tendon and tenolysis. Sensory recovery overall was good. As can be seen in Figure 3 the average distance from the level of injury to the fingertip was the same, which makes comparison of the sensory testing results possible. The moving tests scored better as expected. There was no significant difference between both groups (Fig. 6). The results of the 2-point discrimination test showed the same pattern (Fig. 7).

**Discussion**

The concept of the nerve guide is not new.<sup>3-5,12</sup> For several years many articles about the topic have been



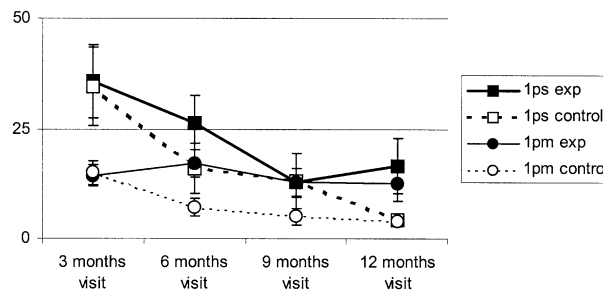
**Figure 4.** Division of patients after randomization based on gap length.



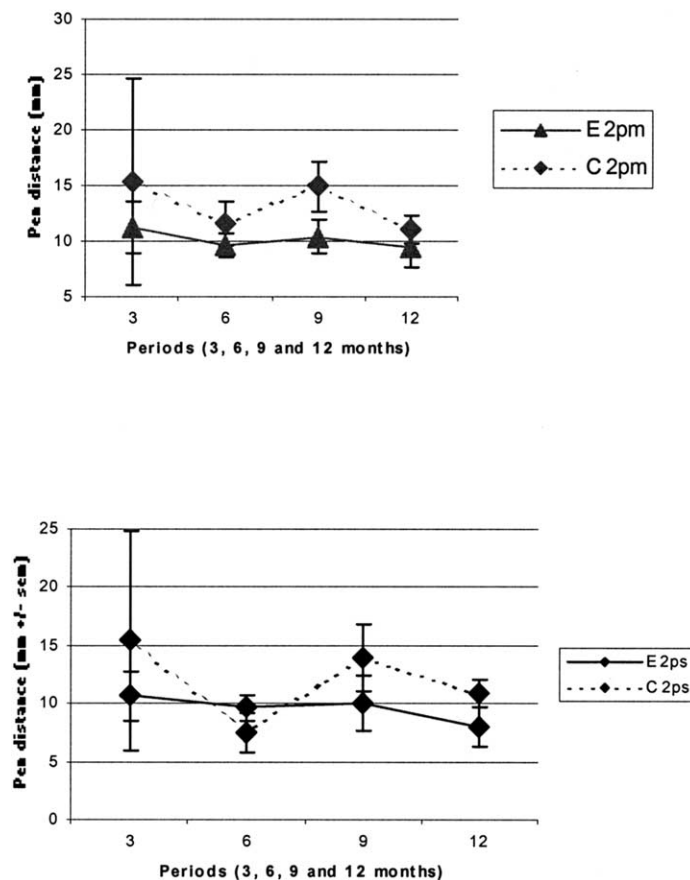
**Figure 5.** Gap length before and after dissection of the nerve stumps and after implantation of the nerve guide (gap length measured through the nerve guide) or control treatment.

published and the value of the guide as a replacement for an autologous nerve graft has been established.<sup>4,7,8,13</sup> Weber et al<sup>14</sup> published their results after using a polyglycolic acid nerve guide in small defects (<4 mm) compared with end-to-end suturing. Despite this, using the nerve guide still is not common practice.

After many years of research considering the safety and optimal composition of the device we present the results of our clinical trial with the Neurolac tube.<sup>7-9,13</sup> This tube differs from other nerve guides in that it is composed of polylactide caprolactone, which does not degrade as quickly as the polyglycolic acid tube. In addition the degradation products are less acidic, which may cause less damage to the surrounding environment. Another advantage is that this tube is transparent, so the position of the nerve stumps can be checked after suturing and the surgeon can confirm that no blood clots are between the stumps, preventing growth of nerve fibers. There is a small learning curve in how to handle the tube in the best, most comfortable way. Placing the tube in warm water before suturing and using a suture with a



**Figure 6.** Sensory recovery by sensory testing measurement during follow-up examination. Y-axis, pressure in g/mm<sup>2</sup> applied needed for the patient to feel; x-axis, months after surgery. 1ps, 1 point static; 1pm, 1 point moving.



**Figure 7.** Results of 2-point discrimination. Y-axis, distance (in millimeters) between the pins; x-axis, months postoperatively.

cutting needle facilitates the surgery. A gap (mean, 8 mm) remained in the nerve guide group because the stumps are drawn into the tube for only a few millimeters. This does not seem to affect the outcome and might be responsible for a better outcome after 12 months because of a lack of tension on the repair or a positive neurotrophic effect.<sup>15-17</sup> Although there is no consensus on when to use a nerve graft it was surprising to discover that a nerve transplant was not used as often as expected even though there were patients with a preoperative gap of 20 mm. It seems that surgeons prefer to perform the end-to-end coaptation with the finger flexed to release tension instead of using a graft, thereby preventing two neuroorrhaphies. The time needed for performing the end-to-end neuroorrhaphy was shorter than the suturing procedure of the tube. This may be explained partly by the learning curve. There were more wound healing problems in the nerve guide group, most probably caused by more severe lesions. The treating surgeon did not consider any of the lesions to be device related. The nerve guide is well accepted by the implantation site. After implantation no hindrance caused by the presence of the tube was reported.

The results of the Neurolac trial show that handling and implantation of this nerve guide are good and that our results are promising. Whether the use of the Neurolac nerve guide when compared with end-to-end repair is beneficial because of the lack of tension and the simplicity of the procedure remains to be seen. Our results indicate that nerve gaps of 2 cm can be treated with a nerve guide instead of a nerve graft but further research considering this topic and longer defects needs to be performed.

The authors would like to thank Dr. Auke de Boer, Dr. Peter Houpt, Dr. Berend van der Lei, and Professor Marco J. P. F. Ritt for coordinating the trial in their hospitals, and Jan Bart B. Hak, PhD, for his guidance and help.

## References

1. Krarup C, Archibald SJ, Madison RD. Factors that influence peripheral nerve regeneration: an electrophysiological study of the monkey median nerve. *Ann Neurol* 2002;51:69-81.
2. Navarro X, Verdú E, Rodríguez FJ, Ceballos D. Artificial nerve graft for the repair of peripheral nerve injuries. *Neurol Sci* 2001; 22(suppl):S7-S13.
3. Hudson TW, Evans GRD, Schmidt CE. Engineering strategies for peripheral nerve repair. *Clin Plast Surg* 1999;26: 617-628.

4. Meek MF, Coert JH. Clinical use of nerve conduits in peripheral-nerve repair: review of the literature. *J Reconstr Microsurg* 2002;18:97-109.
5. Borkenhagen M, Stoll RC, Neuenschwander P, Suter UW, Aebischer P. In vivo performance of a new biodegradable polyester urethane system used as a nerve guidance channel. *Biomaterials* 1998;19:2155-2165.
6. Evans GRD. Challenges to nerve regeneration. *Semin Surg Oncol* 2000;19:312-318.
7. Ijkema-Paassen J, Jansen K, Gramsbergen A, Meek MF. Transection of peripheral nerves, bridging strategies and effect evaluation. *Biomaterials* 2004;25:1583-1592.
8. Den Dunnen WFA, Meek MF, Robinson PH, Schakenraad JM. Peripheral nerve regeneration through P(DLLA- $\epsilon$ -CL) nerve guides. *J Mat Sci* 1998;9:811-814.
9. Den Dunnen WFA, Van der Lei B, Schakenraad JM, Stokroos I, Blaauw E, Bartels H, et al. Poly(DL-lactide- $\epsilon$ -caprolactone) nerve guides perform better than autologous nerve grafts. *Microsurgery* 1996;17:348-357.
10. Robinson PH, Van der Lei B, Hoppen HJ, Leenslag JW, Pennings AJ, Nieuwenhuis P. Nerve regeneration through a two-ply biodegradable nerve guide in the rat and the influence of ACTH4-9 nerve growth factor. *Microsurgery* 1991;12:412-419.
11. Dellon ES, Keller KM, Moratz V, Dellon AL. Validation of cutaneous pressure threshold measurements for the evaluation of hand function. *Ann Plast Surg* 1997;38:485-492.
12. Mackinnon SE, Dellon AL. Clinical nerve reconstruction with a bioabsorbable polyglycolic acid tube. *Plast Reconstr Surg* 1990;85:419-424.
13. Meek MF, Dijkstra JR, Den Dunnen WFA, Ijkema-Paassen J, Schakenraad JM, Gramsbergen A, et al. Functional assessment of sciatic nerve reconstruction: biodegradable poly-(DLLA- $\epsilon$ -CL) nerve guides versus autologous nerve grafts. *Microsurgery* 1999;19:381-388.
14. Weber RA, Breidenbach WC, Brown RE, Jabaley ME, Mass DP. A randomized prospective study of polyglycolic acid conduits for digital nerve reconstruction in humans. *Plast Reconstr Surg* 2000;106:1036-1044.
15. Heijke GCM, Klopper PJ, Van Doorn IBM, Baljet B. Processed porcine collagen tubulization versus conventional suturing in peripheral nerve reconstruction: an experimental study in rabbits. *Microsurgery* 2001;21:84-95.
16. Lundborg G, Rosén B, Abrahamson SO, Dahlin L, Danielsen N. Tubular repair of the median nerve in the human forearm: preliminary findings. *J Hand Surg* 1994;19B:273-276.
17. Wang W, Crain GM, Baylis W, Tsai TM. Outcome of digital nerve injuries in adults. *J Hand Surg* 1996;21A:138-143.