

First metatarsophalangeal hemiarthroplasty for hallux rigidus

Eric Giza · Martin Sullivan · Dan Ocel ·
Gregory Lundeen · Matt Mitchell · Lauren Frizzell

Received: 5 February 2010 / Revised: 19 March 2010 / Accepted: 23 March 2010
© The Author(s) 2010. This article is published with open access at Springerlink.com

Abstract There is a paucity of objective information in the literature about first metatarsophalangeal (MTP) hemiarthroplasty. The authors postulate that it is a reasonable treatment option for severe hallux rigidus in selected patients. Twenty-two elective first MTP hemiarthroplasties were performed on 20 patients that met the inclusion criteria. Pre- and postoperative evaluations were done using the American Orthopaedic Foot and Ankle Society (AOFAS)

forefoot score, visual analogue scale (VAS) pain score, range of motion (ROM) measurements, and radiographs. Average ROM and dorsiflexion improved by 15° and 8°, respectively. VAS pain scores improved from 5 to 2.5 after six weeks. Painless ambulation occurred after six weeks, with maximum improvement by six months. After 24 months, two patients had pain at the surgical site interfering with function, leading to an unsatisfactory result that required conversion to arthrodesis. First MTP hemiarthroplasty for severe hallux rigidus can be considered an alternative to fusion in properly selected patients who wish to maintain a functional range of motion.

M. Sullivan
Foot & Ankle Clinic, St. Vincent's Private Clinic,
438 Victoria Street,
Darlinghurst, Sydney, NSW 2010, Australia

E. Giza (✉) · G. Lundeen
Department of Orthopaedics, University of California, Davis,
4860 Y Street, #3800,
Sacramento, CA 95817, USA
e-mail: eric.giza@ucdmc.ucdavis.edu

D. Ocel
Cornerstone Orthopaedics and Sports Medicine,
Foot and Ankle Service,
80 Health Park Drive Suite 230,
Louisville, CO 80027, USA

G. Lundeen
Reno Orthopaedic Clinic, University of Nevada Reno,
555 N. Arlington Ave.,
Reno, NV 89503, USA

M. Mitchell
Casper Orthopedics,
4140 Centennial Hills Blvd,
Casper, WY 82604, USA

L. Frizzell
University of California, Davis School of Medicine,
4610 X Street,
Sacramento, CA 95817, USA

Introduction

The choices for management of hallux rigidus depend upon the degree of first metatarsophalangeal (MTP) joint arthritis. Joint-sparing procedures such as cheilectomy or metatarsal and phalangeal osteotomies are successful during the initial stages of hallux rigidus (grades I and II); however, the predictability of success from these procedures decreases with advanced disease (grades III and IV) [1–3]. Options for severe hallux rigidus include excisional arthroplasty, such as the Keller procedure, as well as soft tissue interposition arthroplasty, arthrodesis and MTP joint arthroplasty [4–9]. Although each of these procedures can be successful in a selective group of patients, each has its limitations. Keller excisional arthroplasty can offer patients a relatively simple postoperative recovery, but the procedure can result in transfer metatarsalgia, cock-up toe deformity, and a shortened first ray. Therefore, it is usually recommended for low-demand, elderly patients or as a revision option [10]. Soft tissue interposition arthroplasty is also an option, as it can preserve some joint motion [8]. A

recent study compared the clinical and radiological outcome of 22 feet treated by interposition arthroplasty in 30 feet treated with the Keller procedure. The mean follow-up period was 15 months. No statistically significant difference was found between either group concerning patient satisfaction, clinical outcome, and increased range of motion (ROM) of the first MTP joint [11]. Rezie et al. found that the percentage of satisfied or very satisfied patients with the cosmetic results of the Keller-Brandes arthroplasty was >66.7% in 118 patients after an average of 9.1 years [12].

Arthrodesis is considered the gold standard treatment for pain relief in severe hallux rigidus. Complications include nonunion (10%), malposition of the phalanx, limitation of recreational activities, and, in particular, stress on adjacent joints [6, 13]. In young patients, arthrodesis can limit shoe wearing and sporting activities. The primary advantage of MTP arthroplasty is the restoration of functional joint motion. Many different models and materials have been introduced for these replacements, yet outcome studies for these implants are limited by a lack of long-term results. Furthermore, implant failure can lead to catastrophic loss of bone stock and difficult salvage procedures [14].

The BioPro® (BioPro, Port Huron, MI, USA) first MTP joint hemiarthroplasty was introduced in 1952 by Townley and Tanarow, who implanted 312 prostheses over a 40-year period. They reported 93% of cases with good or excellent clinical results with follow-up of up to 33 years [1]. In that study, most hemiarthroplasty failures (11 of 13) occurred in patients with hallux valgus and rheumatoid arthritis, and encouraging long-term results were found in properly selected patients. However, their study lacked a prospective collection of data and objective information for patient selection and outcomes. The goal of this investigation was to determine whether the MTP hemiarthroplasty provided significant pain relief and functional restoration in patients with severe hallux rigidus.

Patients and methods

Twenty-two cases of hallux rigidus in 20 patients were referred to a tertiary foot and ankle centre. Diagnosis was based on history, examination, and degenerative changes on three-view weight-bearing foot radiographs. Each set of radiographs was graded I–IV using the method of Coughlin and Shurnas (Table 1) [3, 15]. First MTP arthrodesis or first MTP hemiarthroplasty were offered to patients with severe pain on ambulation, restricted joint ROM, grade III or IV radiographs, and failure of at least six months of conservative treatment (Fig. 1). The senior author routinely performed both operations, so each patient was given information regarding both the hemiarthroplasty procedure and arthrodesis. Each patient was then allowed to make his or her own

choice regarding the surgical procedure, and all were given the option to decline surgical intervention. Patients who elected hemiarthroplasty over arthrodesis and who were willing to participate were included in the study. Exclusion criteria included sesamoid-MTP arthritis, previous MTP infection, inflammatory arthropathy, hallux valgus, failed MTP joint fusion, and impaired peripheral circulation.

All study patients signed an informed consent form that was approved by the hospital ethics committee. Participants were evaluated preoperatively with a questionnaire that included the AOFAS hallux MTP–interphalangeal score and a visual analogue scale (VAS) pain score. Range of motion of the first MTP joint was assessed by a senior physiotherapist using the method of Hopson, which measures MTP motion relative to the metatarsal axis [16]. Hemiarthroplasty with the BioPro implant (BioPro) procedure was performed as previously described [17] (Fig. 2) by the senior author (MS). Care was taken to preserve proximal phalanx bone stock by removing only the width of the implant, which is approximately 2–3 mm. Implant size was measured, and when in between sizes, the smaller option was chosen. A metatarsal head cheilectomy was performed as needed to maximise ROM.

Twenty-two hemiarthroplasties were performed on 20 patients available for a 24-month follow-up. The average age at the time of surgery was 61 (range 46–80) years. The procedure was performed on 11 right and 11 left feet in 13 women and seven men. Patients were symptomatic for an average of 42.4 (range 6–144) months prior to surgical intervention. Preoperative radiological grading revealed 14 grade III and eight grade IV joints. Postoperatively, all patients were placed in a stiff-soled shoe for 14 days and encouraged to bear weight as tolerated. At 12–14 days following surgery, sutures were removed, the patient was allowed normal shoes, and referred to a structured physiotherapy program aimed at increasing mobility of the first MTP joint and resuming normal gait [17]. VAS pain score and ROM were repeated at six, 12, 26, and 52 weeks, along with the AOFAS forefoot questionnaire at

Table 1 Radiographic grading system for hallux rigidus [17, 18]

Grade	Criteria
I	Minimal or no dorsal osteophytes Minimal flattening of the first metatarsal head
II	Moderate dorsal osteophytes Minimal joint-space narrowing
III	Severe dorsal osteophytes Irregular joint-space narrowing Subchondral cyst formation
IV	Severe dorsal osteophytes Absent joint space

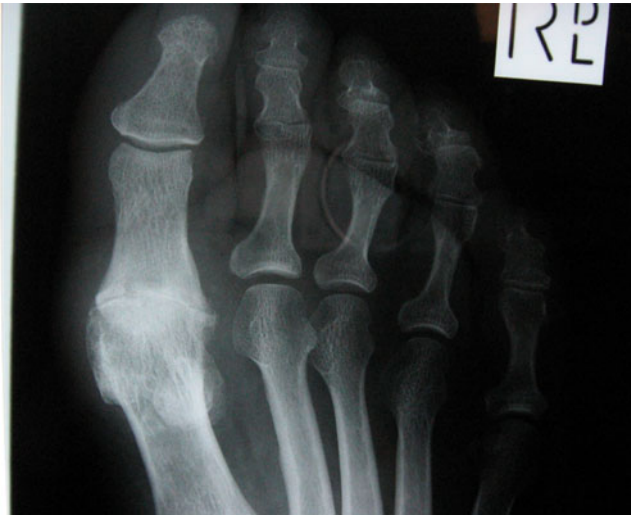

Fig. 1 Preoperative anteroposterior (AP) radiograph of patient with grade IV arthritis of the first metatarsophalangeal joint

six and 12 months. All patients were contacted again at 24 months and questioned as to whether their functional status or pain had changed since the one-year follow-up. Any patient complaining of increased pain or worsening functional status was reassessed clinically. Due to the large geographic catchment area of the tertiary foot and ankle centre, all but two patients declined a 24-month follow-up visit. Data was analysed by statistical tests via the GraphPad Prism 4.00 program, Microsoft Access and Microsoft Excel (Seattle, WA, USA). Significance was accepted at $p < 0.05$ unless indicated otherwise.

Results

The average ROM (Table 2) of each joint improved 15° , from 32.7° preoperatively to 48.1° postoperatively ($p < 0.0001$). ROM further increased an average of 1° between the six month and one year follow-up visits, which was not significantly different ($p > 0.05$) (Table 2). The mean preoperative resting angle of $20 \pm 12^\circ$ was not significantly different from any of the postoperative interval measurements. Dorsiflexion improved from $41 \pm 11^\circ$ preoperatively to $49 \pm 10^\circ$ at six weeks ($p < 0.05$). There was no significant improvement in dorsiflexion beyond the six week measurement to one year. Plantarflexion was improved by $5 \pm 7^\circ$ at three months ($p < 0.05$) and $2 \pm 9^\circ$ at 12 months ($p < 0.01$), although there was no significant difference between these results ($p > 0.05$). Thus, ROM improved during the first three months without a significant change thereafter (Fig. 3).

The average AOFAS scores (Table 2) improved from 61 (range 35–80) preoperatively to 80 (range 67–100) at the six month follow-up ($p < 0.001$). At 12 months, the

average AOFAS score increased to 86 (range 75–95) ($p < 0.0001$); however, this was not statistically different from the six month measurements ($p > 0.05$) (Fig. 4).

VAS pain scores (Fig. 5) improved from 4.7 ± 2.6 preoperatively to 2.5 ± 1.9 at six weeks ($p < 0.0001$), representing a 53% decrease in pain from the preoperative scores. There was no statistical improvement in the VAS from six weeks to one year postoperatively ($p > 0.05$).

There were four complications requiring medical intervention for a total complication rate of 18%. One patient (4%) had a superficial wound infection, which resolved with intravenously administered antibiotics. Postoperative stiffness requiring manipulation under anaesthesia was encountered in three patients (14%). One-year ROM and AOFAS scores of these three patients were not significantly different compared with patients without complications ($p > 0.05$). Mild transfer metatarsalgia under the second MTP joint occurred in one patient who had significant hallux interphalangeus, requiring only conservative treatment. Radiographic evaluation after one year demonstrated no loosening or subsidence of any implants (Fig. 6).

At the two year follow-up, two patients (two arthroplasties) reported deterioration due to pain at the operation site. This was attributed to sesamoid arthritis pain that increased secondary to the increased postoperative mobility of the MTP joint. Both patients were treated with explantation of the implant and arthrodesis. The remaining 20 patients reported no changes from their one year results.

Discussion

Once conservative measures for the treatment of hallux rigidus fail, the surgeon has a myriad of options, which depend largely on the severity of the disease. For grades I and II disease, joint-sparing procedures such as



Fig. 2 Photograph of the first metatarsophalangeal implant

Table 2 Range of motion and American Orthopaedic Foot and Ankle Society (AOFAS) results

	Preoperative	6months postoperative	12months postoperative
Range of motion			
Mean	32.7	47.1**	48.1**
Standard deviation	10.7	9.3	10.6
Range	3–49	25–64	25–62
95% confidence interval for mean	28.0–37.5	42.5–51.8	43.2–52.9
AOFAS			
Mean	61.1	80.2*	86.1**
Standard deviation	12.7	8.3	6.8
Range	35–80	67–100	75–95
95% confidence interval for mean	55.4–66.9	75.9–84.3	83.0–89.1

* $p < 0.001$ compared with pre-operative data, ** $p < 0.0001$ compared with pre-operative data

osteotomy and cheilectomy have been reported to have very successful early and long term results [1–3]. For more severe disease, interpositional arthroplasty procedures have also demonstrated favourable results [18], but arthrodesis of the first MTP joint has long been the treatment of choice for grades III and IV hallux rigidus, with success rates of 77–100% [6, 13]. Fusion success rates are high (92–100%), with the best results obtained from rigid, internal fixation [6]. Complications of arthrodesis include malalignment, nonunion, and subsequent degeneration of the hallux interphalangeal joint [6, 10, 13].

In a retrospective study, Raikin et al. compared the outcome of patients with severe first MTP arthritis who received arthrodesis versus first MTP hemiarthroplasty with the BioPro implant (BioPro). In the arthrodesis group, 87% of patients had a satisfactory result compared with only 60% of hemiarthroplasty patients [19]. Hemiarthroplasty had a failure rate of 24%; complications were dorsal subsidence, plantar callus under the second metatarsal, and second and third MTP instability [19]. Revisions were made to address pain and aseptic loosening of the implant. In the arthrodesis group, all fusions were healed by 12 weeks following surgery, with no surgical revisions; however, complications included irritation caused by the screw head, leading to subsequent removal, plantar callus,

and instability of the second MTP joint [19]. Although arthrodesis of the first MTP can alleviate pain associated with severe arthritis and restore function, it eliminates MTP joint motion and affects normal gait mechanics, which may not be ideal for all patients.

In contrast to the findings of Raikin et al., Sorbie and Saunders performed a prospective study on 23 patients with severe hallux rigidus using a cemented phalangeal hemiarthroplasty [20]. The average preoperative AOFAS improved from 57 (range 39–80) to 88 (range 75–100) at a follow-up ranging from 34 to 72 months. They reported no perioperative complications except for a small haematoma, and only one patient required further surgery after three years for worsening of a pre-existing tendency to hallux valgus. They concluded that a hemiarthroplasty retained joint mobility, strength, and alignment while relieving pain. They found no evidence of component loosening or osteolysis at an average follow-up of 68 months [20]. Our findings of two painful implants requiring fusion after two years more closely mirror the results of Sorbie and Saunders.

Various implant designs for the MTP joint have been proposed, such as the silastic hemiprosthesis, silastic hinged

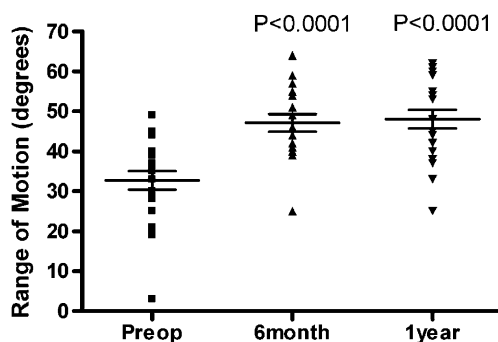


Fig. 3 Range of motion scores preoperatively and 6 months and 12 months postoperatively

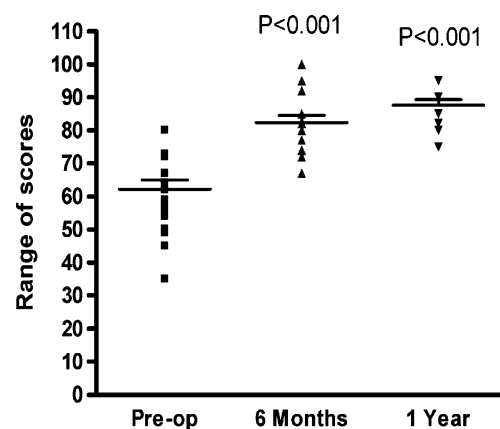


Fig. 4 American Orthopaedic Foot and Ankle Society (AOFAS) scores preoperatively and 6 months and 12 months postoperatively

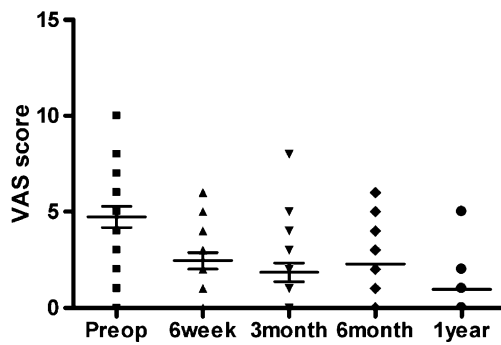


Fig. 5 Visual analogue scale pain scores preoperatively to 1 year postoperatively

prosthesis, metal hemiprosthesis, and nonconstrained metal–polyethylene total endoprosthesis—with most having limited success [21]. Clinical experience with silastic implants has been disappointing, as numerous reports are now available detailing silicone synovitis, lymphadenitis, implant fragmentation, and extensive osteolysis [22]. Koenig and Horwitz reported on the initial results in 61 patients with the Biomet (Biomet, Inc., Parsippany, NJ, USA) total toe system, an unconstrained cobalt chrome/ultra-high-weight polyethylene (UHWPE) device. They reported excellent results in 83.5% using a new scoring system; however, postoperative ROM and average length of follow-up were not clearly documented [23]. Olms and Dietze reported two year follow-up results in 21 patients with the Bio-Action (OsteoMed, Addison, TX, USA) great-toe implant, an unconstrained metal on UHWPE total joint system. Approximately 1–1.5 cm of bone is removed with this system. They reported an average range of postoperative dorsiflexion of 50°. Furthermore, they noted areas of bone resorption on postoperative follow up X-rays that may have represented early loosening [24]. Ess et al. reported two year follow up on ten patients with the ReFlexion (OsteoMed) unconstrained titanium–polyethylene implant [21]. They reported satisfactory results in 60% of patients and an improvement in dorsiflexion by an average of 25°. Complications included malalignment, stiffness, and revision requiring bone graft. Merkle and Sculco reported on a semiconstrained metal/UHWPE prosthesis (designed and fabricated at the Hospital for Special Surgery, New York, NY, USA) with follow-up of at least 12 months. They reported a 54.5% loosening rate and a satisfaction rate of only 36% [5].

Biomechanically, the first MTP joint is not a direct weight-bearing articulation; however, high compressive loads are produced by associated muscle action [4]. Furthermore, it is subject to flexion/extension abduction/adduction and pronation/supination forces [4, 25]. Shear stress is dissipated by dorsal gliding of the phalanx on the native metatarsal head, which spares the joint during gait, making it an ideal joint for hemiarthroplasty [1]. Prostheses that replace the metatarsal

head are subjected to both shear stresses and compressive forces, putting them at risk of loosening and failure [4, 21, 23, 24]. An important advantage of the first MTP hemiarthroplasty is replacement of only the proximal phalangeal articular surface, resulting in maintenance of toe length and minimal bone-stock resection (usually <2 mm). Therefore, if revision to arthrodesis is subsequently necessary, it is unlikely to require structural bone grafting or excessive shortening of the first ray. Stability is achieved by retaining the intact plantar soft tissue structures, including insertion of the flexor hallucis brevis, which has been associated with failure in the Keller procedure with excessive phalangeal resection. None of the patients in this study had problems of instability, either subjectively or objectively. In addition, the procedure is unlikely to alter the weight-bearing characteristics of the metatarsal head and result in transfer metatarsalgia.

Patients undergoing hemiarthroplasty need to maximise motion postoperatively with physical therapy until they are able to perform their ROM and strengthening exercises on their own. All patients were sent to the same physiotherapist for the postoperative protocol. Despite this, three patients (14%) had postoperative stiffness requiring manipulation under anaesthesia. Their result at the completion of the study did not appear to be significantly affected.

Although patients with sesamoid arthritis present on radiographs were not offered hemiarthroplasty, two patients who did not appear to have significant degenerative disease preoperatively did develop symptoms after surgery. Therefore, the authors now routinely obtain a computed tomography (CT) scan preoperatively to evaluate the sesamoid

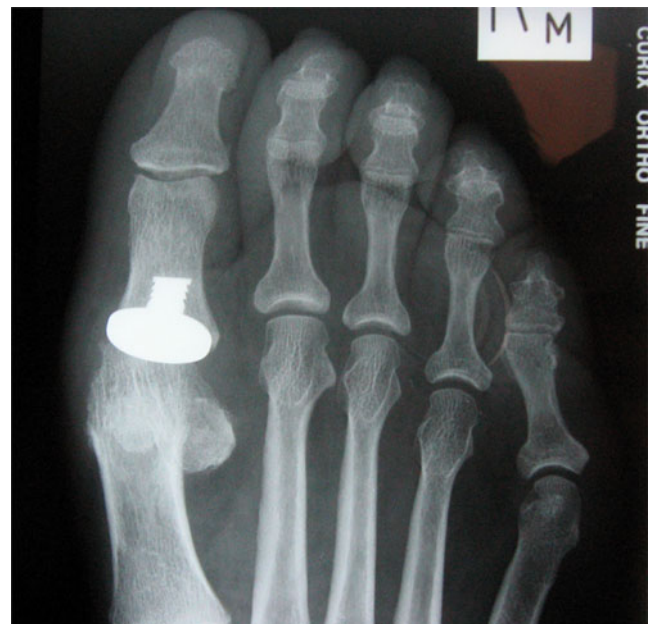

Fig. 6 Postoperative anteroposterior (AP) radiograph of patient 12 months after a first metatarsophalangeal hemiarthroplasty

articulation. In conclusion, the authors consider hallux–sesamoid arthritis a contraindication for hemiarthroplasty.

One weakness of this investigation is the lack of objective, repeat AOFAS scoring at two years. Although 20 of 22 patients reported no change in functional or pain status at the two year phone interview, a subsequent objective scoring of AOFAS scores is required to prove statistical maintenance of the results after two years. A five year follow-up study is underway.

Conclusions

This study identified that first MTP hemiarthroplasty is a reasonable option for surgeons treating patients with severe hallux rigidus who wish to maintain normal joint mechanics and who would otherwise be considered for an arthrodesis procedure. This investigation demonstrated significant improvement in ROM and AOFAS forefoot scores. The authors recommend that the use of the MTP hemiarthroplasty be limited to patients with hallux rigidus and that it be avoided in those with hallux–sesamoid arthritis, hallux valgus, and inflammatory arthritis.

Open Access This article is distributed under the terms of the Creative Commons Attribution Noncommercial License which permits any noncommercial use, distribution, and reproduction in any medium, provided the original author(s) and source are credited.

References

1. Townley CO, Taranow WS (1994) A metallic hemiarthroplasty resurfacing prosthesis for the hallux metatarsophalangeal joint. *Foot Ankle Int* 15:575–580
2. Smith RW, Katchis SD, Ayson LC (2000) Outcomes in hallux rigidus patients treated nonoperatively: a long-term follow-up study. *Foot Ankle Int* 21:906–913
3. Coughlin MJ, Shurnas PS (2003) Hallux rigidus. Grading and long-term results of operative treatment. *J Bone Joint Surg AM* Vol 85-A:2072–2088
4. Johnson KA, Buck PG (1981) Total replacement arthroplasty of the first metatarsophalangeal joint. *Foot Ankle* 1:307–314
5. Merkle PF, Sculco TP (1989) Prosthetic replacement of the first metatarsophalangeal joint.[see comment]. *Foot Ankle* 9:267–271
6. Coughlin MJ, Abdo RV (1994) Arthrodesis of the first metatarsophalangeal joint with Vitallium plate fixation. *Foot Ankle Int* 15:18–28
7. Granberry WM, Noble PC, Bishop JO et al (1991) Use of a hinged silicone prosthesis for replacement arthroplasty of the first metatarsophalangeal joint.[see comment]. *J Bone Joint Surg AM* Vol 73:1453–1459
8. Coughlin MJ, Shurnas PS (2003) Hallux rigidus: demographics, etiology, and radiographic assessment. *Foot Ankle Int* 24:731–743
9. Hamilton WG, O'Malley MJ, Thompson FM et al (1997) Roger Mann Award 1995. Capsular interposition arthroplasty for severe hallux rigidus. *Foot Ankle Int* 18:68–70
10. Coughlin MJ, Mann RA (1987) Arthrodesis of the first metatarsophalangeal joint as salvage for the failed Keller procedure. *J Bone Joint Surg AM* Vol 69:68–75
11. Schenk S, Meizer R, Kramer R et al (2009) Resection arthroplasty with and without capsular interposition for treatment of severe hallux rigidus. *Int Orthop* 33:145–150
12. Reize P, Schanbacher J, Wulker N (2007) K-wire transfixation or distraction following the Keller-Brandes arthroplasty in Hallux rigidus and Hallux valgus? *Int Orthop* 31:325–331
13. Coughlin MJ (1990) Arthrodesis of the first metatarsophalangeal joint with mini-fragment plate fixation. *Orthopedics* 13:1037–1044
14. Kitaoka HB, Holiday AD Jr, Chao EY et al (1992) Salvage of failed first metatarsophalangeal joint implant arthroplasty by implant removal and synovectomy: clinical and biomechanical evaluation. *Foot Ankle* 13:243–250
15. Coughlin M (1999) Arthritic conditions. In: Coughlin M, Mann R (eds) *Surgery of the foot & ankle*. Mosby, St Louis, pp 560–650
16. Hopson MM, McPoil TG, Cornwall MW (1995) Motion of the first metatarsophalangeal joint. Reliability and validity of four measurement techniques. *J Am Podiatr Med Assoc* 85:198–204
17. Giza E, Sullivan M (2005) First metatarsophalangeal hemiarthroplasty for grade III & IV hallux rigidus. *Tech Foot Ankle Surg* 4:10–17
18. Berlet GC, Hyer CF, Lee TH et al (2008) Interpositional arthroplasty of the first MTP joint using a regenerative tissue matrix for the treatment of advanced hallux rigidus. *Foot Ankle Int* 29:10–21
19. Raikin SM, Ahmad J, Pour AE et al (2007) Comparison of arthrodesis and metallic hemiarthroplasty of the hallux metatarsophalangeal joint. *J Bone Joint Surg Am* 89:1979–1985
20. Sorbie C, Saunders GA, Sorbie C et al (2008) Hemiarthroplasty in the treatment of hallux rigidus. *Foot Ankle Int* 29:273–281
21. Ess P, Hamalainen M, Leppilahti J (2002) Non-constrained titanium-polyethylene total endoprosthesis in the treatment of hallux rigidus. A prospective clinical 2-year follow-up study. *Scand J Surg* 91:202–207
22. Verhaar J, Vermeulen A, Bulstra S et al (1989) Bone reaction to silicone metatarsophalangeal joint-1 hemiprosthesis. *Clin Orthop Relat Res* 245:228–232
23. Koenig RD, Horwitz LR (1996) The Biomet Total Toe System utilizing the Koenig score: a five-year review. *J Foot Ankle Surg* 35:23–26
24. Olms K, Dietze A (1999) Replacement arthroplasty for hallux rigidus. 21 patients with a 2-year follow-up. *Int Orthop* 23:240–243
25. Mann RA (1980) Surgical implications of biomechanics of the foot and ankle. *Clin Orthop Relat Res* 146:111–118